

Implant Survival after Preparation of the Implant Site Using a Single Bur: A Case Series

Raphaël Bettach, DDS;* Silvio Taschieri, MD, DDS;† Gilles Boukhris, DDS;‡ Massimo Del Fabbro, BSc, PhD§

ABSTRACT

Background: Implant site preparation usually consists of several consecutive drilling steps, performed using different burs with increasing diameter.

Purpose: The purpose of the present study was to report the clinical outcomes of edentulous patients that underwent implant treatment, in which a special bur that allows preparation of the implant site in a single drilling step was used.

Material and Methods: One hundred forty-nine patients (79 males, 70 females, mean age 51.8 ± 12.2 [SD] years, range 20–80 years) have been rehabilitated using different oral surgery procedures. A total of 350 implants were inserted (171 in the maxilla and 179 in the mandible). A barrier membrane was used for covering a total of 126 implants. Fifteen implants were placed by using the osteotome technique and 52 by using the lateral sinus lift procedure. Eighty-nine implants were placed in postextraction sockets. Thirty-six implants underwent immediate loading. Implant survival, peri-implant bone level change, and patients' satisfaction were the main variables assessed.

Results: No patient dropout occurred. The mean follow-up on a patient basis was 21.5 ± 3.1 months (range 12–27 months). A total of seven implant failures were recorded in six patients, leading to a mean implant survival of 98.0% (96.0% on a patient basis). The mean peri-implant bone loss after 1 year was 0.58 ± 0.44 mm ($n = 282$). Apart from implant failures, no biological nor mechanical complications occurred. All patients demonstrated full satisfaction.

Conclusions: The use of a single bur for implant site preparation allows the reduction of the time needed for the surgical procedure, without compromising the clinical outcomes. Further, long-term comparative studies are needed to confirm the results of this study.

KEY WORDS: dental implants, implant site preparation, implant survival, surgical drills

INTRODUCTION

The use of dental implants for the treatment of edentulism continues to increase worldwide and over the years has evolved into a predictable procedure, which is rapidly becoming the preferred method of tooth

replacement. In addition to function restoration, there is increased awareness of and demand for esthetics in traditional restorative dentistry as well as implant-related care. Predictable delivery of highly esthetic, naturally appearing implant restorations is dependent on a number of factors, some of which are related to the morphology and to hard and soft tissue quality of the intended implant site and others to the implant features or to some steps of the surgical protocol.

Implant site development is a very important phase of the surgical procedure. A minimally traumatic procedure is recommended for preserving as much as possible the healing potential of bone and soft peri-implant tissues and to reduce crestal bone loss as well. Hence implant site preparation becomes critical for achieving a predictable osseointegration and for obtaining a pleasing natural implant restoration. Among the factors correlated to implant site preparation, the rising of the

*Adjunct associate professor, New York University, New York, NY, USA, and private practice, Gretz-Armainvilliers, France; †visiting professor, Department of Biomedical, Surgical and Dental Sciences, University of Milan, and Chief of the Section of Endodontics and Implant Surgery, Dental Clinic, IRCCS Istituto Ortopedico Galeazzi, Milan, Italy; ‡private practice, Paris, France; §researcher, University of Milan, and Director of the Research Center for Oral Health, Department of Biomedical, Surgical and Dental Sciences, IRCCS Istituto Ortopedico Galeazzi, Milan, Italy

Reprint requests: Dr. Massimo Del Fabbro, Istituto Ortopedico Galeazzi, University of Milan, Via Riccardo Galeazzi 4, 20161 Milan, Italy; e-mail: massimo.delfabbro@unimi.it

© 2013 Wiley Periodicals, Inc.

DOI 10.1111/cid.12082

temperature during drilling has long been identified as critical to preservation of the surrounding tissue.¹⁻⁴ A temperature of 47°C for 1 minute in fact has been reported to cause bone necrosis at the drilling site.³ The latter may hinder osseointegration process and is one of the most credited reasons for excessive early peri-implant bone loss, which may compromise implant stability as well as facilitate bacterial infiltration and peri-implantitis.⁵ Control of the heat generation may be achieved using irrigation with cool water, and adopting a correct combination between the drill rotation speed, the drilling time, the bur angulation, and the pressure applied during site preparation.⁶⁻⁹ In particular, it has been suggested that a combination of high rotation speed and a large applied force may be desirable as this allows a faster site preparation and a minimum increase of temperature as compared with lower rotation speed and pressure.^{6,7} Such factors, in turn, are dependent on the bone quality at the intended implant site, by the site depth and by the features of the bur, like diameter, shape, and above all the sharpness of the threads.⁹⁻¹⁶ Sharp burs may reduce friction force generation which is likely to produce heating of the site. Drill wear may also be an issue in heat generation at the drilling site.^{17,18}

Correct preparation of the implant site ensures efficient and accurate installation. Incremental site preparation using a sequence of increasing diameter drills has long been characterized as an implant site preparation technique. However, using a host of drills for any single implant may become boring for clinicians, especially when multiple implants are to be placed, and for the patient as the duration of the intervention may be excessively long, causing discomfort. Furthermore, prolonged tissue exposure may be detrimental to the postoperative course due to the increased release of pro-inflammatory cytokines and consequent amplified inflammatory response.¹⁹ Therefore, any simplification of the techniques for site preparation can be favorably accepted by both clinicians and patients. Some improvements of the drill design and drilling technique have been proposed in order to reduce the risk of overheating the implant site and simplify the procedure.²⁰⁻²² Recently, a four-bladed drill with a special design, which allows to prepare implant site with a single drilling step in different types of bone, has been introduced in the market.

The purpose of the present report is to describe our clinical experience with such type of drill in a number of clinical applications for the implant treatment of

partially and totally edentulous patients. Here, clinical and radiographic outcomes as well as patient satisfaction after at least 1 year of follow-up are reported.

MATERIALS AND METHODS

This report is based on a series of patients consecutively treated at a single private practice office in Paris. All patients were rehabilitated by means of implant-supported prostheses, for different indications. All cases were treated by a single clinician with more than 10 years of experience in implant dentistry. The patients were treated following the principles embodied in the World Medical Association Helsinki Declaration of 1975 for biomedical research involving human subjects, as revised in 2000.²³

Patients' inclusion criteria were the following:

- at least 18 years of age;
- absence of general medical contraindications for oral surgery procedures (American Society of Anesthesiologists ASA-1 or ASA-2);
- full-mouth bleeding score and full-mouth plaque score less than 25% at baseline;
- partially or totally edentulous or in need for extraction in order to be rehabilitated by means of implant-supported prostheses;
- absence of ongoing infection at the intended implant site or sinus pathologies for those scheduled for maxillary sinus augmentation; and
- able to sign the informed consent form.

Patients were excluded if they presented one of the following exclusion criteria:

- any systemic disease, condition, or medication that might compromise healing or implant osseointegration;
- inability or unwillingness to return for follow-up visits; and
- inability or unwillingness to maintain a good level of oral hygiene throughout the study.

The following clinical procedures were performed, according to conventionally accepted protocols: guided bone regeneration (GBR) with implants placed simultaneously or in a second surgical phase; maxillary sinus elevation using the crestal approach (osteotome technique); maxillary sinus elevation using the lateral approach with implants placed simultaneously or in a second surgical phase; single-tooth implants placed

in fresh postextraction sites (type I according to the Hammerle classification²⁴) with either immediate or delayed restoration; single-tooth implants placed in extraction sockets after healing of soft tissues (type II implants); multiple tooth extraction and immediate implant placement and restoration (partial prosthesis); full bridges with immediate loading. All patients underwent cone beam CT before surgery as a routine diagnostic approach in order to carefully evaluate the available bone at the intended surgical site and planning the correct implant size and three-dimensional orientation.

All patients received prophylactic antibiotic therapy consisting of 2 g of amoxicillin (or clindamycin 600 mg if allergic to penicillin) 1 hour before the implant placement procedures. All patients rinsed for 1 minute with chlorhexidine digluconate mouthwash 0.2% prior to the surgery. Local anesthesia was induced using articaine with adrenaline 1:100.000.

The surgical procedure started with a minimal full-thickness flap elevation with marginal incisions extended to one tooth mesial and one tooth distal to the implant site without vertical incisions.

In case of implants immediately inserted in fresh postextraction sites, after atraumatic tooth extraction the socket was debrided and the implant carefully placed in the correct prosthetically driven position, with the implant platform leveled 1 mm below the marginal level of the buccal wall.

Implant site preparation was always performed using specially designed cylindro-tapered drills with four bladed edges (ID^{ALL} drills, Implant Diffusion International, Montreuil, France) (Figure 1). These drills are available with four drilling lengths (10, 12, 15, 18 mm) characterized by different color codes, and three different diameters (3.8, 4.2, 5.2 mm). They allow a single drilling procedure before implant placement in soft and normal bone (types II–IV), and up to two drilling steps with two increasing diameters in dense bone (type I). The drilling sequence is shown in Figure 2, A–C. The recommended rotation speed is 1,500 rpm and cooling is obtained by copious irrigation with physiological solution. Such four-bladed drill is used without in-and-out movements.

All implants (ID^{ALL}, Implant Diffusion International) were made of TiAl6V titanium alloy with a sandblasted acid-etched and TiO₂ coated surface. Such implants had the following features: a switched platform, a cylindrical-tapered shape, an aesthetic gold



Figure 1 Four-bladed drill used in the present study. The red band indicates 10-mm drilling length.

polished neck, a Morse taper connection, an anti-unscrewing groove, double twist threads, and a catch base with large threads and tapered core. They are recommended for use in postextraction sockets and are specially designed for self-tapping, in order to optimize the achievement of primary stability in any type of bone density, and favoring the immediate loading protocols. The recommended rotation speed of the implant during insertion is 15 to 20 rpm.

After implantation, the surgical flaps were sutured, achieving a soft tissue primary closure. Sutures were removed 1 week later and the patients were seen monthly for prophylaxis. All patients continued to take the antibiotic postoperatively – 1 g amoxicillin (or 300 mg clindamycin) twice a day for 5 days. They also took nonsteroidal anti-inflammatory drugs if needed. Chlorhexidine digluconate mouthwash twice a day was prescribed for 3 weeks postsurgery.

Follow-Up

Patients were scheduled for follow-up visits at 6 months after loading, 12 months, and once a year thereafter, up to

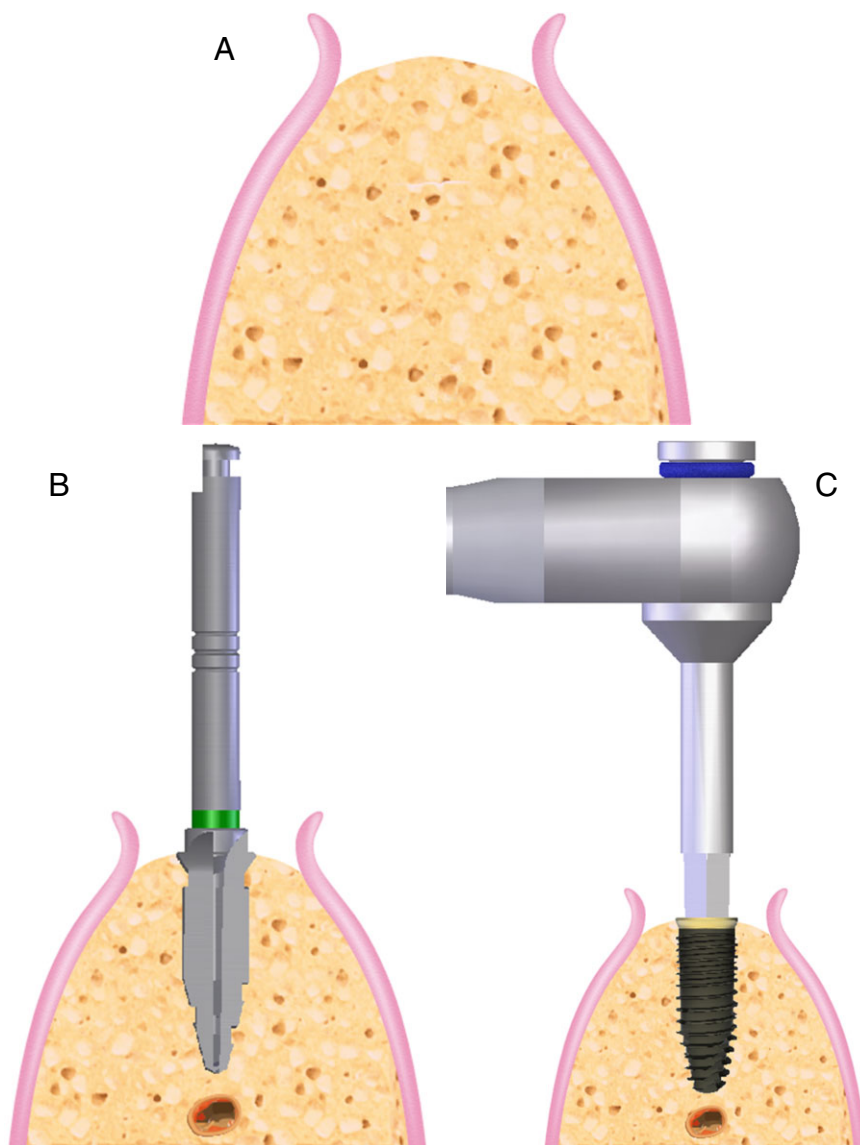


Figure 2 Drilling sequence. *A*, Flap elevation with ridge exposure. *B*, Site preparation using one single bur. *C*, Implant insertion at low-speed rotation.

5 years. Orthopantomograms and periapical radiographs were taken at implant insertion; periapical radiographs were then taken at the prosthesis delivery and at each scheduled follow-up visit. Periapical radiographs were taken using a long-cone paralleling technique and an individual X-ray holder (bite block) to ensure reproducibility.

The outcome variables under study were:

- Prosthesis success. The prosthesis is functional, even if one or more implants have failed. No mobility nor pain is present. At each follow-up visit, prosthesis stability was tested by means of two opposing instruments' pressure.
- Implant survival. The implant is in function and stable. No evidence of peri-implant radiolucency, no suppuration or pain at the implant site, or ongoing pathologic processes is present.
- Implant success. The success criteria proposed by Buser and colleagues²⁵ and Cochran and colleagues²⁶ were adopted for each implant, at each follow-up visit. These criteria were: (a) no clinically detectable mobility when tested with opposing instrument pressure; (b) no evidence of peri-implant radiolucency; (c) no recurrent or persistent peri-implant infection; (d) no complaint of pain; and (e) no complaint of neuropathies or paresthesia.

- Occurrence of complications. They include both biological complications, such as peri-implant mucositis, peri-implantitis, fistula or abscess, and mechanical or prosthetic complications like fracture of the implant and/or of any prosthetic component, screw loosening.
- Marginal bone level change. Intraoral radiographs were scanned at 600 dpi with a scanner (Epson Perfection Pro, Epson Italia SpA, Roma, Italy) and the peri-implant bone level was assessed with an image analysis software (UTHSCSA Image Tool version 3.00 for Windows, University of Texas Health Science Center in San Antonio, TX, USA) by an experienced evaluator. The known distance between the screw threads or the length of the implant was used to calibrate each image. The implant platform was used as the reference for each measurement. Radiographs taken at the prosthesis delivery served as the baseline for evaluation of the marginal bone level change over the study period. The linear axial distance between implant platform and the most coronal bone-to-implant contact was measured. In order to have a single value for each implant, mesial and distal values were averaged.
- Oral hygiene level. The presence of plaque and bleeding on probing was evaluated at four surfaces per each tooth or implant and expressed as percentage of positive sites over total sites (full-mouth score).
- Postoperative course. One week after surgery, patients were asked to take a few minutes for a survey investigating the most common items related to quality of life in the postsurgical period. Such items were: pain (on a 0–100 visual analog scale), tissue swelling, analgesic drugs taken.
- Patient satisfaction. Aesthetics, mastication function, and phonetics were assessed after 1 year of loading using a questionnaire. Each item was rated according to a five-point Likert-type scale choosing among the following possible answers: excellent, very good, good, sufficient, or poor.

Statistical Analysis

The 1-year outcomes of the different types of rehabilitation were compared using the Pearson's chi-square test, considering the implant as the analysis unit, and assuming $p = .05$ as the significance level. In particular, the following comparisons were made: implants in fresh

extraction sites versus healed sites; implants simultaneous to GBR procedure versus implants placed in a second surgical session respect to GBR; postextraction implants with immediate versus delayed restoration; lateral approach for maxillary sinus augmentation with simultaneous versus delayed implant placement; crestal approach versus lateral approach for maxillary sinus augmentation. Kaplan–Meier statistics (life table analysis) was used to assess the implant cumulative survival rate throughout the study.

RESULTS

Based on the selection criteria, 149 patients (79 females and 70 males) were treated from September 2010 to December 2011. Patients' mean age was 51.8 ± 12.2 years (range 20–82 years). Each patient accounted for a single prosthetic rehabilitation. A total of 350 implants have been inserted. All implant sites were prepared using a single drill. Table 1 resumes the number of implants placed for each type of rehabilitation. One hundred seventy-one implants have been placed in the maxilla and 179 in the mandible. Figures 3 and 4 show the distribution of implants per each site in the maxilla and mandible, respectively. The mean follow-up was 21.6 ± 3.1 months (range 12–27 months). No patient dropped out to date.

Bone type distribution according to the Lekholm and Zarb classification²⁷ was: 39% type II, 52% type III, 9% type IV.

A total of seven implant failures were recorded, for an overall implant cumulative survival of 98.00% on an implant basis (Table 2), and of 95.97% on a patient basis. Prosthesis success was 99.3%. All failures occurred within 4 months of implant placement. Two of them occurred in a 59-year-old woman who smoked more than 10 cigarettes/day. She underwent immediate implant placement in fresh extraction sockets and immediate restoration with provisional crowns. The other five failures did not compromise prosthesis function. One of them occurred in a patient with a full bridge that was placed in function according to an immediate loading protocol. The remaining four failures were recorded during healing phase. The failed implants were replaced by implants of similar size that achieved osseointegration and were restored without further complications. No biological or mechanical complication was recorded to date.

TABLE 1 Summary of the Outcomes of the Different Surgical Procedures

Type of Rehabilitation	No. of Implants	No. of Failures	Implant Survival (%)
Implants in healed sites	32	0	100
GBR and implants the same day	54	1	98.1
GBR and implants in two different surgical steps	72	1	98.6
Osteotome technique for sinus lift	15	1	93.3
Lateral sinus lift with delayed implant placement	38	0	100
Lateral sinus lift with simultaneous implant placement	14	0	100
Type II postextraction implants	27	0	100
Type I postextraction implants with delayed restoration	14	1	92.8
Type I postextraction with immediate delivery of provisional crown	28	2	92.8
Postextraction on partially edentulous with provisional crown	20	0	100
Full bridge with immediate loading	36	1	97.2
	350	7	98.0

GBR, guided bone regeneration.

No significant difference in implant survival was found between postextraction implants and implants placed in healed sites ($p = .84$), nor between postextraction implants submitted to immediate or delayed restoration ($p = .93$). Also for reconstructive procedures like sinus augmentation and GBR, no difference in survival was found between implants placed simultaneously or in a subsequent surgical session ($p = 1.00$ for both procedures), nor between lateral and crestal approach to maxillary sinus augmentation ($p = .51$).

The mean peri-implant bone loss evaluated after 1 year of function was 0.58 ± 0.44 mm ($n = 282$ implants). The remaining 61 implants could not be evaluated due

to poor quality of the radiographs that did not allow a precise assessment of the peri-implant bone level.

Postsurgical quality of life survey was available for 145 patients (97.3%). Only patients submitted to the maxillary sinus augmentation procedure with lateral approach had pain levels higher than 30/100 in the first 4 days, and took analgesics in the same period. They also reported swelling in the first 3 days. Conversely, patients undergoing other surgical procedures reported pain levels of less than 20/100 since the first day postsurgery, and took negligible amounts of analgesics. Also, the swelling was negligible in the first 2 days and absent thereafter.

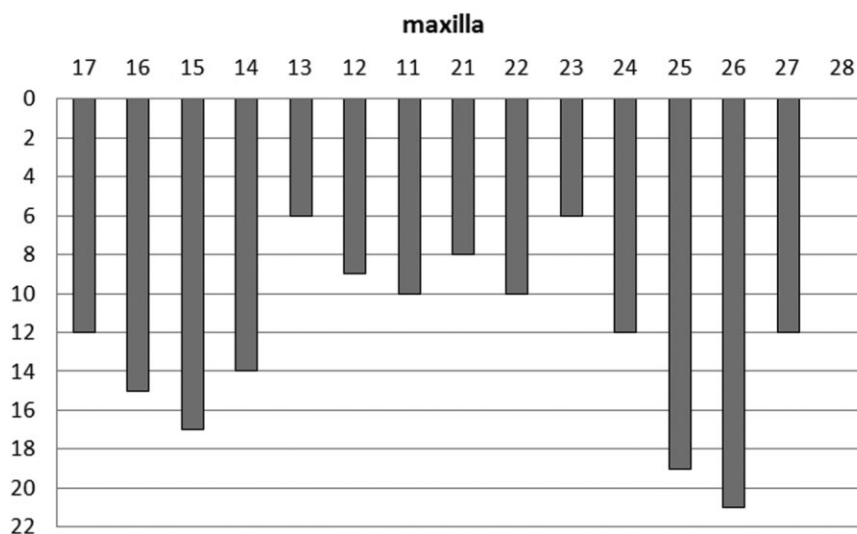


Figure 3 Implant distribution in the maxilla.

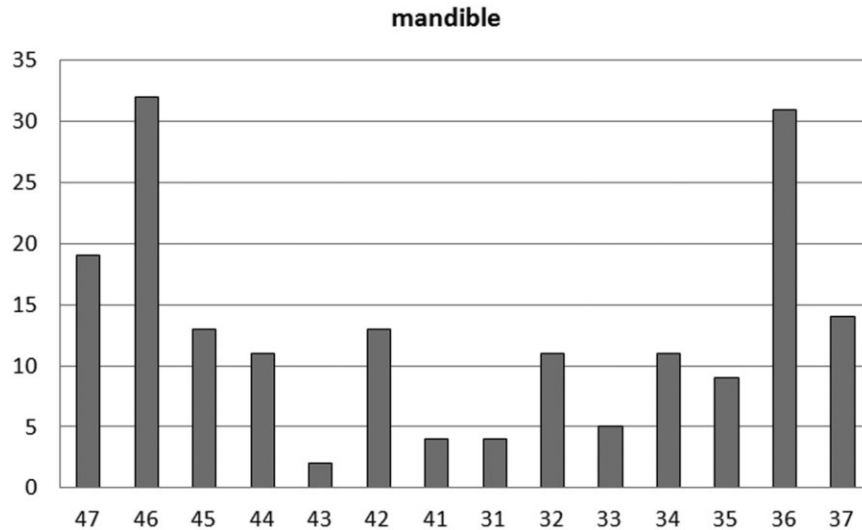


Figure 4 Implant distribution in the mandible.

A total of 138 questionnaires (92.6% of patients) were evaluated. Patient satisfaction after 1 year of function was very high. A score of “excellent” or “very good” (pooling together these two answers) was reported in 97.8%, 94.9%, and 99.3% for aesthetics, mastication function, and phonetics, respectively.

DISCUSSION

This study reports excellent clinical and radiographic results using a special drill for the preparation of the implant site. It may be speculated that such a fast drilling phase, causing a decrease of the overall surgical time in which tissues remain exposed, also reduces tissue suffering. This may lead to better tissue preservation, reduced postoperative discomfort, and better patient acceptance of the treatment.

Excessive heating of the surgical site during drilling has been advocated to be detrimental for tissue healing, causing excessive bone loss.¹⁻⁵ The temperature increase is also related to bone density that is to the hardness of

the bone tissue and its resistance to drilling. The latter depends on the local bone composition, namely the ratio between cortical and cancellous bone.^{13,14,28} The thicker the cortical layer, the harder the bone and the higher the risk of causing elevated temperatures when drilling. For this reason, it has been recommended to adopt different protocols for implant site preparation, in relation to bone tissue density.^{13,14} Conventional protocols consist of different numbers and types of drills used and different rotation speed. It has been observed that the use of sharp drills, in combination with high rotation speed, allows the creation of the implant site in a very short time, reducing the risk of developing excessive heat.^{15,20,22} Conversely, the use of worn burs makes it difficult to create a breach into the bone, with a consequent prolonged tissue exposure to heat, which, in turn, increases the risk of bone necrosis. According to the manufacturer, the drills used in the present study can be used at least 50 times in dense bone without reducing their performance, without showing signs of wear and

TABLE 2 Life Table Analysis

Months from placement	No. of implants	No. of failures	No. of dropout	Interval survival (%)	Cumulative survival (%)
0–6	350	7	0	98.0	98.0
6–12	343	0	0	100	98.0
12–18	338	0	0	100	98.0
18–24	326	0	0	100	98.0
24–30	140	0	0	100	98.0

deformation and without causing excessive high temperatures at the drilling site. This well compares with a previous in vitro study reporting that stainless steel and ceramic burs can be safely used up to 100 times before showing signs of wearing that might compromise their cutting efficiency.¹⁷

With the drill type used in the present study, no excessive bone loss around implants has been observed and 98% of the implants have remained stable during the observation period.

The drills used in the present study, however, have some limitations. In fact, with the incremental site preparation technique it is possible to correct the axis properly, in case the first few drills have created a misaligned implant site. Hence, with modification of the drilling axis of the larger burs the final site can fit the original project of the treatment plan. With a reduced number of steps, down to a single drilling phase, a greater precision is required as it is not possible to correct misalignments. Therefore, it can be recommended to adopt a surgical mask to drive the bur properly, at least for the early procedures, for a learning curve is required even in case of experienced surgeons.

In the present study, very restrained postsurgical symptomology was reported. The pain levels, swelling, and the amount of analgesics taken by the patients were very low, with patients demonstrating a high acceptance of the treatment. The 1-year questionnaire also proved that the treatment was very satisfying to patients, which expressed positive judgments for both esthetic and functional aspects. These excellent results may be at least in part due to the minimally invasive implant site preparation procedure proposed in this study. Speeding up and simplifying the clinical procedure may allow a better control of tissue suffering and of the related local inflammatory process, minimizing postoperative pain and swelling. Furthermore, minimally invasive procedures may preserve the healing potential of the tissues, improving and accelerating implant osseointegration and soft tissue healing, with positive consequences for both implant functionality and aesthetic appearance of the restoration.

Furthermore, no significant difference in clinical outcomes was found among different types of implant-based rehabilitations. It may be speculated that the present minimally invasive surgical procedure for implant placement may contribute to achieve a highly predictable clinical outcome in several types of implant-based clinical applications.

CONCLUSION

One-step drilling may lead to excellent outcomes, with advantages for the surgeon in terms of simplification of the implant site preparation technique and speeding up of the surgical procedure, and for the patient as well, due to faster treatment time and decreased postsurgical tissue suffering, which may lead to better acceptance of the implant therapy.

REFERENCES

1. Rafel SS. Temperature changes during high-speed drilling on bone. *J Oral Surg Anesth Hosp Dent Serv* 1962; 20:475–477.
2. Matthews LS, Hirsch C. Temperatures measured in human cortical bone when drilling. *J Bone Joint Surg Am* 1972; 54:297–308.
3. Eriksson RA, Adell R. Temperatures during drilling for the placement of implants using the osseointegration technique. *J Oral Maxillofac Surg* 1986; 44:4–7.
4. Brägger U, Wermuth W, Török E. Heat generated during preparation of titanium implants of the ITI Dental Implant System: an in vitro study. *Clin Oral Implants Res* 1995; 6:254–259.
5. Oh T-J, Yoon J, Misch CE, Wang H-L. The causes of early implant bone loss: myth or science? *J Periodontol* 2002; 73:322–333.
6. Abouzia MB, James DF. Measurements of shaft speed while drilling through bone. *J Oral Maxillofac Surg* 1995; 53: 1308–1316.
7. Abouzia MB, Symington JM. Effect of drill speed on bone temperature. *Int J Oral Maxillofac Surg* 1996; 25:394–399.
8. Brisman DL. The effect of speed, pressure, and time on bone temperature during the drilling of implant sites. *Int J Oral Maxillofac Implants* 1996; 11:35–37.
9. Yacker M, Klein M. The effect of irrigation on osteotomy: depth and bur diameter. *Int J Oral Maxillofac Implants* 1996; 11:634–638.
10. Abouzia MB, James DF. Temperature rise during drilling through bone. *Int J Oral Maxillofac Implants* 1997; 12:342–353.
11. Cordioli G, Majzoub Z. Heat generation during implant site preparation: an in vitro study. *Int J Oral Maxillofac Implants* 1997; 12:186–193.
12. Reingewirtz Y, Szmukler-Moncler S, Senger B. Influence of different parameters on bone heating and drilling time in implantology. *Clin Oral Implants Res* 1997; 8:189–197.
13. Misch CE, Dietsch-Misch F, Hoar J, Beck G, Hazen R, Misch CM. A bone quality-based implant system: first year of prosthetic loading. *J Oral Implants* 1999; 25:185–197.
14. Misch CE, Qu Z, Bidez MW. Mechanical properties of trabecular bone in the human mandible: implications for dental implant treatment planning and surgical placement. *J Oral Maxillofac Surg* 1999; 57:700–706.

15. Tehemar SH. Factors affecting heat generation during implant site preparation: a review of biologic observations and future considerations. *Int J Oral Maxillofac Implants* 1999; 14:127–136.
16. Sharawy M, Misch CE, Weller N, Tehemar S. Heat generation during implant drilling: the significance of motor speed. *J Oral Maxillofac Surg* 2002; 60:1160–1169.
17. Ercoli C, Funkenbusch PD, Lee HJ, Moss ME, Graser GN. The influence of drill wear on cutting efficiency and heat production during osteotomy preparation for dental implants: a study of drill durability. *Int J Oral Maxillofac Implants* 2004; 19:335–349.
18. Oliveira N, Alaejos-Algarra F, Mareque-Bueno J, Ferrés-Padró E, Hernández-Alfaro F. Thermal changes and drill wear in bovine bone during implant site preparation. A comparative in vitro study: twisted stainless steel and ceramic drills. *Clin Oral Implants Res* 2012; 23:963–969.
19. Penarrocha M, Garcia B, Marti E, Balaguer J. Pain and inflammation after periapical surgery in 60 patients. *J Oral Maxillofac Surg* 2006; 64:429–433.
20. Chacon GE, Bower DL, Larsen PE, McGlumphy EA, Beck FM. Heat production by 3 implant drill systems after repeated drilling and sterilization. *J Oral Maxillofac Surg* 2006; 64:265–269.
21. Bubeck KA, García-López J, Maranda LS. In vitro comparison of cortical bone temperature generation between traditional sequential drilling and a newly designed step drill in the equine third metacarpal bone. *Vet Comp Orthop Traumatol* 2009; 22:442–447.
22. Gronkiewicz K, Majewski P, Wisniewska G, Pihut M, Loster BW, Majewski S. Experimental research on the possibilities of maintaining thermal conditions within the limits of the physiological conditions during intraoral preparation of dental implants. *J Physiol Pharmacol* 2009; 60(Suppl 8):123–127.
23. World Medical Association Declaration of Helsinki: ethical principles for medical research involving human subjects. *JAMA* 2000; 284:3043–3045.
24. Hammerle CH, Chen ST, Wilson TG Jr. Consensus statements and recommended clinical procedures regarding the placement of implants in extraction sockets. *Int J Oral Maxillofac Implants* 2004; 19(Suppl):26–28.
25. Buser D, Mericske-Stern R, Bernard JP, et al. Long-term evaluation of nonsubmerged ITI implants. Part 1: 8-year life table analysis of a prospective multi-center study with 2359 implants. *Clin Oral Implants Res* 1997; 8:161–172.
26. Cochran D, Buser D, ten Bruggenkate C, et al. The use of reduced healing times on ITI implants with a sandblasted and acid-etched (SLA) surface. *Clin Oral Implants Res* 2002; 13:144–153.
27. Lekholm U, Zarb GA. Patient selection and preparation. In: Brånemark PI, Zarb GA, Albrektsson T, eds. *Tissue integrated prosthesis: osseointegration in clinical dentistry*. Chicago: Quintessence, 1985; 199–210.
28. Norton MR, Gamble C. Bone classification: an objective scale of bone density using the computerized tomography scan. *Clin Oral Implants Res* 2001; 12:79–84.